

Veterinary Dentistry Basics

Introduction

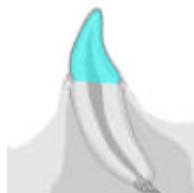This program will guide you, step by step, through the most important features of veterinary dentistry in current best practice.

This chapter covers the basics of veterinary dentistry and should enable you to:

- ✓ Describe the anatomical components of a tooth and relate it to location and function
- ✓ Know the main landmarks important in assessment of dental disease
- ✓ Understand tooth numbering and formulae in different species.

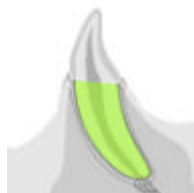Dental Anatomy

Crown



The crown is normally covered by enamel and meets the root at an important landmark called the cemento-enamel junction (CEJ). The CEJ is anatomically the neck of the tooth and is not normally visible.


Root



Teeth may have one or more roots. In those teeth with two or more roots the point where they diverge is called the furcation angle. This can be a bifurcation or a trifurcation.

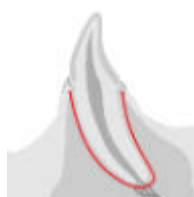At the end of the root is the apex, which can have a single foramen (humans), a multiple canal delta arrangement (cats and dogs) or remain open as in herbivores. In some herbivores the apex closes eventually (horse) whereas in others it remains open throughout life. The apical area is where nerves, blood vessels and lymphatics travel into the pulp.

Alveolar Bone



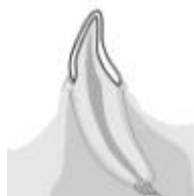The roots are encased in the alveolar processes of the jaws. The process comprises alveolar bone, trabecular bone and compact bone. The densest bone lines the alveolus and is called the cribriform plate. It may be seen radiographically as a white line called the lamina dura.

Lamina Dura



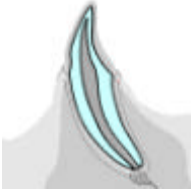Sight of an uninterrupted lamina dura is interpreted radiographically as a sign of good periodontal health.

Enamel



Enamel is 96% inorganic, mainly hydroxyapatite crystals, with 4% water and fibrous organic material. It is the hardest substance in the body and covers the exterior surface of the crowns only. The enamel consists of hexagonal prisms or rods of hydroxyapatite crystals held together by a cementing organic matrix. Enamel is formed by ameloblasts within the tooth bud before eruption. It is capable of only very limited repair when damaged, once the tooth has erupted.

Dentine



Dentine is the main supporting structure of the tooth and is the second hardest tissue in the body after enamel. It is 70% mineral and acellular, as hydroxyapatite crystals, and 30% organic as water, collagen and mucopolysaccharide. The main structure is the **dentinal tubule**, which extends from the external surface to the pulp. There are approximately 30,000 - 40,000 tubules per mm^2 , which can transmit pain to the pulp if the dentine is exposed.

Dentine Types

- Primary dentine forms before tooth eruption.
- Secondary dentine forms after eruption, as the tooth develops with age. It develops from the odontoblasts living within the pulp and is laid down in layers within the pulp cavity.
- Reparative or tertiary dentine forms as a result of trauma to the odontoblasts; this can be thermal, chemical, bacterial or mechanical. Tertiary dentine has few tubules and is darker in colour and very dense in structure.

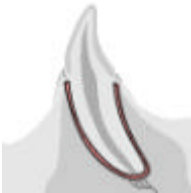Cementum



Cementum covers the enamel free roots and provides a point of attachment for the periodontal ligament. Similar in composition to woven bone it is 45-50% inorganic, primarily as hydroxyapatite crystals, and 50-55% organic material.

Cementum is capable of formation, destruction and repair and remodels continually throughout life. It is nourished from vessels within the periodontal ligament.

Periodontal Ligament

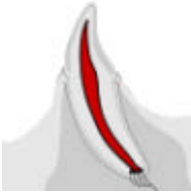

The periodontal ligament is comprised of taut collagen fibre bundles (called **Sharpey's fibres** where they are inserted in cementum and alveolar bone), which are anchored to the cementum of the tooth and the alveolar bone.

There are three distinct categories of periodontal fibres- **gingival**, **trans-septal** and **alveolodental**.

There are blood vessels within the periodontal ligament (PL), which are evenly distributed. There are also nerves that are capable of transmitting heat, cold, pain and pressure in addition to proprioception in some species.

Pulp



This living tissue within the tooth is located in the pulp chambers and root canals. It is well innervated and vascularised and comprises connective tissue, nerves, lymph and blood vessels, collagen and undifferentiated reserve mesenchymal cells (e.g. odontoblasts).

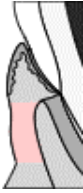Odontoblasts line the pulp cavity and branch into the dentine tubules. These branches, together with the fine nerve endings, cause the dentine to be sensitive to temperature and pain. The odontoblasts lay down dentine and reduce the pulp cavity in size as the animal ages. The pulp is nourished via vessels entering and leaving the root canal at the apical delta and, occasionally, via accessory canals.

Potential Dangers

- Physical trauma: may cause bruising, haemorrhage or pulpitis.
- Accidental over-heating from polishing or scaling: may cause pulp necrosis.
- Pulp exposure after tooth fracture: may cause pulpitis and possibly pulp necrosis.
- Loss of blood supply following trauma: will cause ischaemic necrosis.

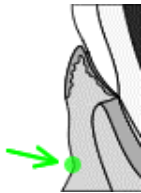Gingival Landmarks

Attached Gingiva



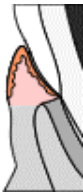The attached gingiva is tightly adherent to the subgingival connective tissue and bone via deep rete pegs. It is keratinised to withstand the stress of ripping and tearing food.

Mucogingival Junction



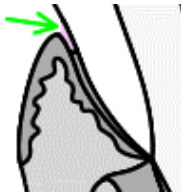
The mucogingival junction (MGJ) is the junction between the soft, fleshy mucus membrane of the oral cavity and the tough, collagen rich gingiva. The MGJ remains stationary throughout life although the gingiva around it may change in height, due to hyperplasia, recession or attachment loss.

Free Gingiva



Free gingiva forms the gingival margin, which is visible during examination. It surrounds the crown of the tooth.

Gingival Sulcus



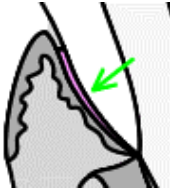
The gingival sulcus is located between the tooth and the free gingival margin and is the crevice that surrounds the tooth.

The sulcus lining epithelium renews itself rapidly every 4-6 days - compared to 6-12 days for oral epithelium. The sulcus is bathed in crevicular fluid, which contains many of the elements of immunity – antibodies, neutrophils, lymphocytes etc.

The normal depth of the sulcus is 0.5mm to 1mm in cats and 1-3mm in dogs. As a rule 1mm for cats and 1-2mm in dogs can be considered normal. Sulcus depth of more than 4mm in the dog means that the tooth is in **danger!**

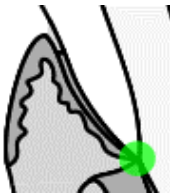
During active disease and attachment loss it is common for the sulcus to deepen. As the junctional epithelium becomes inflamed and oedematous it separates from the root surface. The tissues become infiltrated with the cells normally found in this response – both primary and secondary. The junctional epithelium allows for the migration of polymorphonuclear granulocytes and fluids.

Junctional Epithelium



At the bottom of the sulcus is the junctional epithelium (or epithelial attachment), which is so important in the control of periodontal disease. This attaches the gingival tissues to the tooth using hemidesmosomes. The apical (towards the root) extent of the JE is usually the cemento-enamel junction.

Cemento-enamel Junction



The cemento-enamel junction (CEJ) is the junction between the anatomical crown and root.

In health the junction is not visible. If it is visible, the division between the shiny enamel and the slightly dull root cementum is very clear. The CEJ is normally the apical (towards the root) extent of the junctional epithelium. Therefore sight of the CEJ indicates recession of the attachments of the tooth and is highly significant.

Interdental Papilla

The gingival peak between closely adjacent teeth is called the interdental papilla. This structure prevents impaction of food and debris between closely adjacent teeth (e.g. incisors in dogs) and is a structure that should be preserved during surgery whenever possible.

When viewed from the coronal aspect there is an indentation called the col. The epithelium of the col is not keratinised.

Function of Teeth

Incisors

Incisors are used for cutting, scooping, picking up objects and grooming.

Incisors are small, single-rooted teeth that commonly become mobile when affected by periodontal disease.

Canines

Canines are used for holding prey, display, slashing and tearing when fighting and act as a cradle for the tongue.

Canines form important structures at the front of the mouth. Loss of lower canines is serious as it weakens the rostral mandibles significantly. It also allows the tongue to fall out of the mouth. This can lead to excessive drying and/or trauma to the tongue.

Loss of upper canines, especially in cats, causes the upper lip to fall inward. The lower canine can then occlude lateral to the displaced lip and cause excoriation or punctures.

Premolars

Premolars are used for holding, carrying and breaking food into small pieces.

Looked at from the side, premolars should show a “pinking shear” appearance with the tip of an upper tooth pointing into an interdental space on the lower jaw and vice versa. If they do not do so, it may indicate a bite defect such as mandibular prognathism or brachygnathism.

Molars

Molars are used for grinding food into small pieces with flat occlusal tables.

The masticatory forces in the molar zone of the dog have been estimated to be 300 to 800 psi as passive bite force with a sudden localised bite force when snapping the jaws shut of as much as 30,000 to 80,000 psi.

Molars can be affected by dental caries. This condition has a reported 7% incidence in mature dogs.

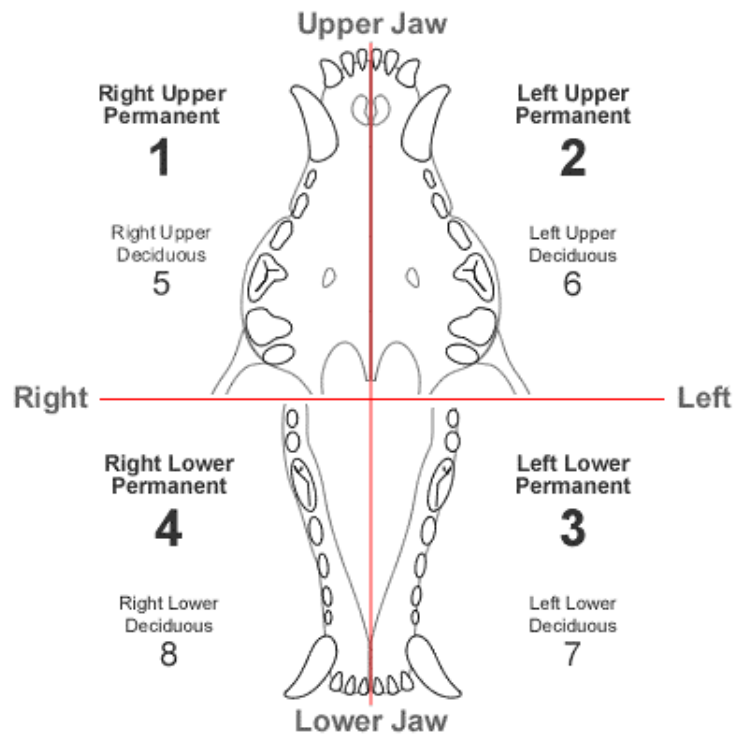
The Modified Triadan System

Tooth Numbering in the Dog

The modified Triadan system provides a consistent method of numbering teeth across different animal species. The system is based on the permanent dentition of the pig, which has 11 teeth in each quadrant - three incisors, one canine, four premolars and three molars. The grand total is 44 teeth.

Quadrant

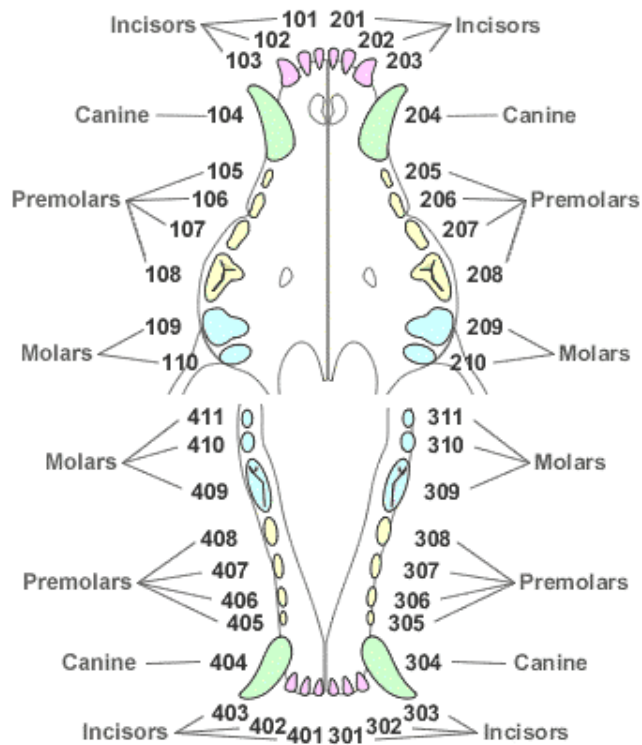
The **first digit** of the modified Triadan system denotes the quadrant.



Tooth Position

The **second and third digits** denote the tooth position within the quadrant, with the sequence always starting at the midline.

The following diagram shows tooth numbering in the dog.



Tooth Numbering in Other Species

Landmarks

Using definite landmarks we can number animals with less teeth, such as domestic cats, horses and rabbits.

The **central incisor is always 01** with the following incisors 02 and 03.

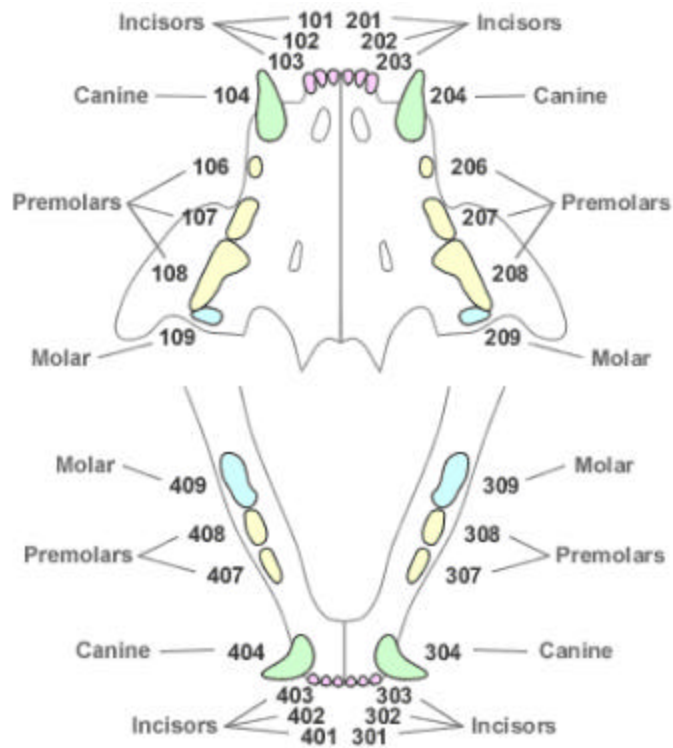
The **canines are always 04**.

The premolars are 05 to 08 and the last premolar present is always 08.

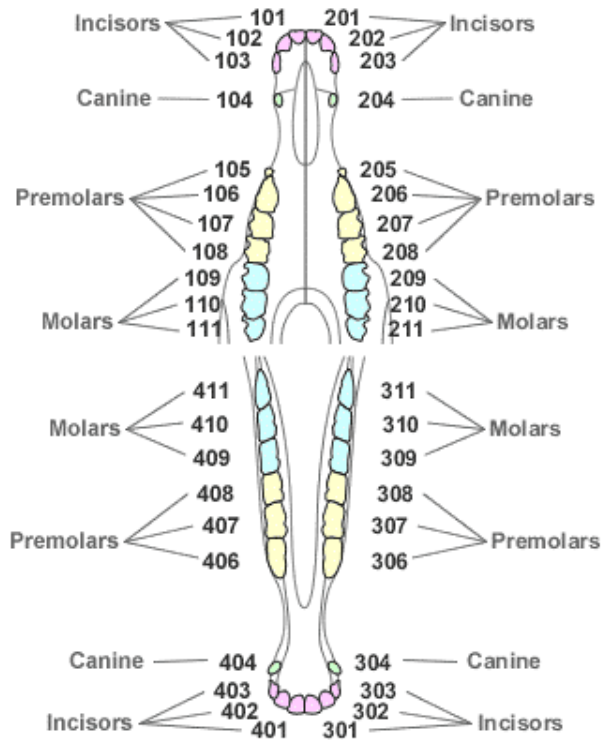
The **first molar is always 09** with the following molars 010 and 011.

Domestic Cat

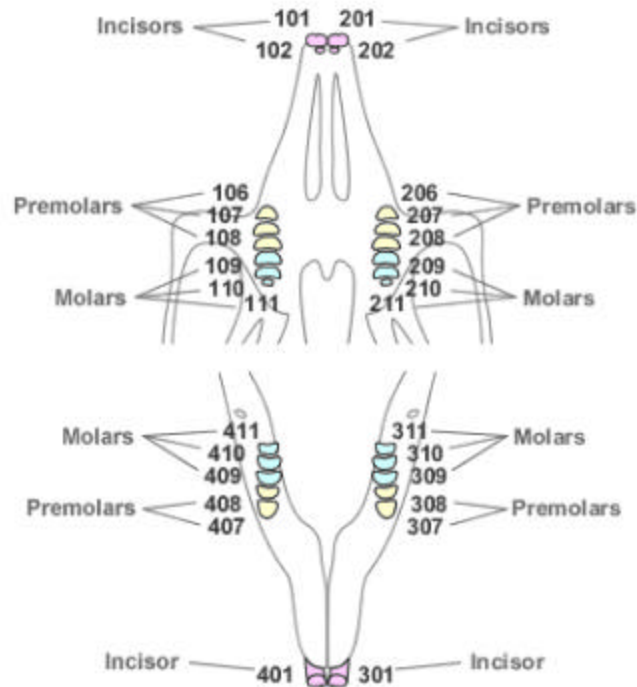
In cats, where tooth numbers are reduced, the use of the carnassials as landmarks will help considerably. The upper carnassials in carnivores are always the last premolars, which are 108 and 208. The lower carnassials in carnivores are always the first molars, 309 and 409.



Horse



Rabbit



Key Points

- ✓ The tooth structure and its surroundings contain key landmarks which are important in assessing the level of disease.
- ✓ Diseased oral structures will generally follow the same pathological pathways as other damaged tissues in the body.
- ✓ Tooth numbering systems form the basis of accurate charting and clinical recording.

Further Reading

- American Veterinary Dental Society, *Journal of Veterinary Dentistry*, 1988 to present.
- Crossley DA and Penman S (eds), *BSAVA Manual of Small Animal Dentistry*, 1995.
- Holmstrom SE, Frost P and Eisner ER, *Veterinary Dental Techniques*, 2nd edition, Saunders 1998.
- Lobprise HB and Wiggs RB, *The Veterinarian's Companion for Common Dental Procedures*, AAHA Press 2000.
- Verstraete FJM, *Self-assessment Colour Review of Veterinary Dentistry*, Manson 1999.
- Wiggs RB & Lobprise HB, *Veterinary Dentistry - principles and practice*, Lippincott 1997.