

Effect of foot balance on the intra-articular pressure in the distal interphalangeal joint *in vitro*

M. J. VIITANEN, A. M. WILSON*, H. P. McGUIGAN, K. D. ROGERS and S. A. MAY

Departments of Farm Animal and Equine Medicine and Surgery and Veterinary Basic Science, The Royal Veterinary College, University of London, Hawkshead Lane, North Mymms, Hatfield, Herts AL9 7TA, UK.

Keywords: horse; distal interphalangeal joint; intra-articular pressure; osteoarthritis

Summary

Reasons for performing study: Increased joint pressure has been implicated in the progression of osteoarthritis.

Hypothesis: That intra-articular pressure in the distal interphalangeal joint (DIP) is significantly higher in legs loaded with heel up (HU), low heel (TU), lateral side up (LU) and medial side up (MU) imbalance compared to the balanced position.

Methods: Twelve elbow down limbs were compressed in a hydraulic loading jig and DIP pressure measured.

Results: Elevating the heels by 5° significantly increased DIP pressure. After 5 ml of contrast was injected into the joint, heel elevation caused a greater increase in DIP pressure and heel lowering decreased DIP pressure. Silicone rubber castings were taken of 20 DIP whilst under load. The articular contact area was localised on the dorsal aspect in the HU position, palmar aspect in the TU position and towards the elevated side with lateromedial imbalance.

Conclusions: Altered foot orientation, which could result from trimming and shoeing, therefore influences intra-articular pressure in the DIP and the articular contact area.

Potential clinical relevance: The results support the view that a balanced foot is the ideal and that the elevated heels may be detrimental to long term viability of the DIP joint.

Introduction

Joint disease is a commonly diagnosed problem in both horse (Rossdale *et al.* 1985) and man (Kramer *et al.* 1983). The end stage is characterised by classic osteoarthritis (OA) with breakdown of articular cartilage, osteophyte formation, inflammation, effusion and pain (Lohmander 1994). The development of this condition, however, is complex and multifactorial, with controversy over the relative importance of the various contributory factors. In both horses and man with late stage OA, joint effusion is often observed. The joint synovial space is constrained by the synovial membrane and, more importantly, the elastic collagenous overlying joint capsule, so an increase in joint fluid volume should result in an increased intra-articular pressure. The intra-articular pressure in the healthy equine MCP-joint, with no observable joint distention, is -2.53 mm Hg (-0.3 kPa) relative to atmospheric pressure (Strand

et al. 1995). Diseased joints, however, have a positive pressure, which can be as high as 116 mmHg (15.3 kPa) in human knee joints (Jawed *et al.* 1997) or 37 mmHg in horses' MCP-joints (Strand *et al.* 1995). A joint space may be divided into separate compartments and intra-articular pressure could, therefore, vary between different joint pouches within a joint. When the synovial fluid volume increases in a joint, both loading and movement result in further pressure rises and, therefore, an increased risk of damage to articular cartilage (Vegter 1987). These changes in volume and pressure during weightbearing and movement are presumably the result of compression of the joint capsule by overlying ligaments and tendons, leading to changes in joint configuration and hence capsule tension. Infusion of as small a volume as 5 ml of saline into the normal human knee joint cavity caused substantial alterations in intra-articular pressure, when joint angle was changed by moving the limb (Wood *et al.* 1988). It has also been shown that increased intra-articular pressure of the synovial fluid causes pain. With hip osteoarthritis, human patients experienced significantly more pain with an elevated intra-articular pressure (Goddard and Gosling 1988). Increased intra-articular pressure may also cause increased intra-osseous pressure which may contribute to pain.

Horses with synovitis/capsulitis and osteoarthritis have increased intra-articular pressures (Strand *et al.* 1998). A slight increase in joint pressure in the static joint has been associated with damage to articular cartilage and release of metalloproteinases. It is difficult to say if the increase in joint pressure actually leads to articular cartilage damage or if the articular cartilage damage and metalloproteinase release lead to increased synovial fluid volume and thus increased intra-articular pressure. Effusion and changes in joint orientation may also compromise the blood supply to the bone (Arnoldi *et al.* 1980).

A common site for OA in the horse is the distal interphalangeal joint (DIP). This joint reacts to insults in the manner of all joints, degenerative disease being the sequel. This occurs only rarely in isolation from other conditions and it is usually masked by their presence (Wyn-Jones 1988). The DIP is a classical hinge joint with its movement largely constrained to a single plane. The joint load distribution and range of movements are, however, influenced by 2 important factors in the foot trimming of horses: 1) Mediolateral foot imbalance which is common due to differences in the foot trimming practices of different farriers and results in changes in the weight distribution under the foot and also higher up the limb

*Author to whom correspondence should be addressed.

TABLE 1: Mean \pm s.e. intra-articular pressure in kPA before any contrast material was injected into the DIP (A) and intra-articular pressure after injecting 5 ml of contrast material into the DIP(B)

	Normal	Heel-up	Toe-up	Lateral-up	Medial-up
A/1000 N	-1.9 \pm 0.1	3.06 \pm 0.4*	-1.9 \pm 0.1	-2.1 \pm 0.1	-2.7 \pm 0.2
B/1000 N	8.4 \pm 1.1	30.9 \pm 3.5*	4.9 \pm 1.1*	12.4 \pm 1.6	13.5 \pm 2.1*
A/2000 N	-2.6 \pm 0.1	7.4 \pm 0.5*	-1.9 \pm 0.1	-0.4 \pm 0.1	-2.1 \pm 0.2
B/2000 N	23.2 \pm 3.6	64 \pm 11.4*	13.3 \pm 3*	29.4 \pm 5	25.2 \pm 3.6

N = Newton. * = statistical difference $P < 0.05$, when compared to normal loading.

TABLE 2: Mean \pm s.e. the area of silicone remaining on the articular surface in each site. Area is shown as mm²

	Dorsal	Palmar	Lateral	Medial
Balanced	2.0 \pm 0.7	3.7 \pm 1.7	3.1 \pm 0.9	2.5 \pm 0.8
Heel-up	2.7 \pm 1.9	24.3 \pm 4.4	11.9 \pm 3.1	15.2 \pm 3
Toe up	26.9 \pm 6.3	2.1 \pm 1.8	14.8 \pm 3.7	14.7 \pm 4.4
Lateromedial	15.6 \pm 4.7	15.2 \pm 7.7	27.2 \pm 7.1	3.6 \pm 0.6

TABLE 3: Mean \pm s.e. the percentage of total silicone weight remaining on the articular joint surface

	Dorsal	Palmar	Lateral	Medial
Balanced	5.3 \pm 1.5	4.3 \pm 1.1	5.3 \pm 1.6	4.2 \pm 1
Heel up	2 \pm 1.4	18.9 \pm 4.5	10.6 \pm 2.6	10.2 \pm 2.8
Toe up	21 \pm 3.6	1.5 \pm 0.9	10.4 \pm 2.2	12.1 \pm 1.7
Lateromedial	18.7 \pm 5.7	6.1 \pm 3.6	3.4 \pm 2.8	19.1 \pm 5

(Firth *et al.* 1988; Wilson *et al.* 1998); 2) Dorsopalmar foot balance (ie the angle at which the hoof meets the ground) is often altered as part of the management regime for conditions such as navicular disease and laminitis (Curtis *et al.* 1999; Hood 1999).

Both of these factors alter the anatomical configuration and mechanical load distribution on the DIP (Degueurce *et al.* 2000). This may also result in changes in the joint volume, i.e. the joint synovial space, which would be of little significance in the normal joint with negative intra-articular pressure. However, in cases with joint effusion and an increased joint fluid volume, imbalance of the hoof could result in an increase in the intra-articular pressure and therefore contribute to damage to articular cartilage.

This study set out to test the hypothesis that both mediolateral imbalance and dorsopalmar imbalance result in elevated pressure in the fluid distended DIP-joint and that this pressure elevation is due to changes in the volume of different compartment/aspects of the joint.

Materials and methods

Study 1

Twelve forelimbs were used from horses with no pathological signs in the distal limb. Limbs were used either fresh ($n = 7$) or thawed after freezing ($n = 5$), assessed macroscopically before the study and dissected after the experiment to assess any gross pathological or conformational changes.

Limbs were sectioned through the distal humerus, perpendicular to the long axis of the limb, at mid stance orientation, 3–5 cm above the elbow joint and a 13 mm diameter hole was drilled vertically down through the elbow joint into the radius. The cadaveric limbs were mounted in a hydraulic loading jig, by means of a 130 mm long, 12 mm diameter pin attached to a hydraulic ram, which provided a 50 mm diameter flat loading surface. This pin locked the elbow joint (Fig 5) to prevent any change in joint angle during loading, but was not rigidly fixed to the ram to allow hinging (Wilson *et al.* 2001).

The hoof of the limb was positioned on a foot-plate. A shear beam force transducer¹ placed under the foot-plate recorded axial

limb force. The signal from the force transducer was amplified via a strain gauge amplifier and logged at 100Hz via software written in LabView². The amplified output from the force transducer was displayed on a volt-meter, so limb force could be controlled during loading cycles.

After mounting the leg in the jig, a 20 gauge needle was inserted through the dorsal articular pouch into the DIP. Intra-articular pressure was measured by connecting the needle to a fluid filled cannula and three-way-tap, in turn connected to a solid state pressure transducer (286-709)³. The output from the pressure transducer was also logged via LabView. Each limb was loaded to 1000 Newton, which approximates the limb vertical force generated during standing by a 450 kg horse and to 2000 N, the peak force experienced when the horse is walking (Merkens *et al.* 1993). The hoof was first positioned in its normal 'balanced' weightbearing position and the pressure was measured. Using a 5° angle plastic wedge, the hoof angle was then altered to heel up (HU), low heel (TU), lateral side up (LU) and medial side up (MU) imbalance. Sequence of wedging was applied randomly. Intra-articular synovial pressure was recorded with the legs loaded at 1000 and 2000 N in each position.

In a preliminary study, in 5 limbs, the articular pressure was measured with 4 needles inserted through the dorsal pouch, via a palmar approach through the navicular bursa and through a lateral approach to the DIP joint, respectively. Pressure measurements were made in a limb in all orientations.

With 12 legs, 5 ml of contrast material (Urografin 370)⁴ was injected into the joint and measurements made. Contrast material was injected through the same needle as that used for measurements and measurements were made within 10 min of injecting the contrast material. In eight of these 12 legs, the intra-articular pressure was measured before injecting the contrast material into the joint, in all 5 orientations, at 1000 and 2000 N force.

Study 2

The loading apparatus used in Study 1 was used in the silicon casting study. Twenty-eight forelimbs were used. In the pilot study in the initial group of 8 legs, 15 ml of silicone rubber casting material (494-146)³ was injected into the joint. In the second

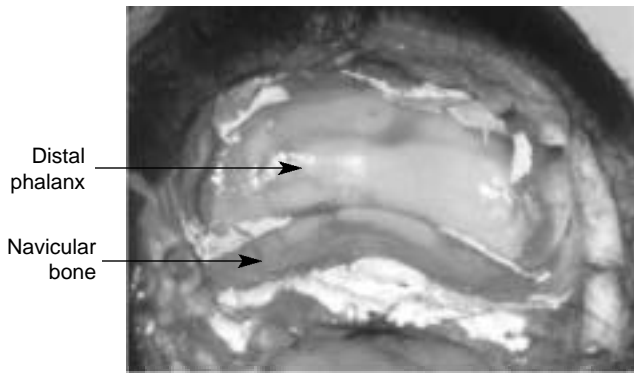


Fig 1: Silicone cast showing the contact area in balanced hoof.

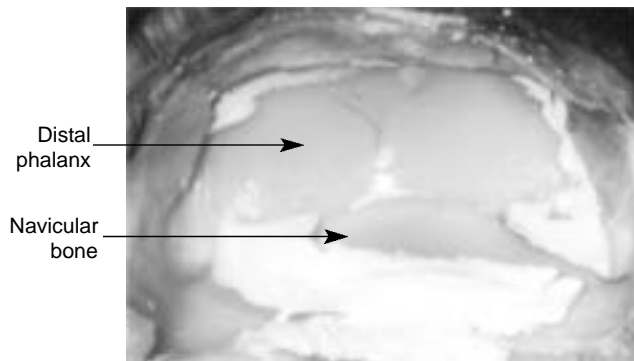


Fig 2: Silicone cast showing the contact area in heel-up orientation.

group, 20 legs were used and 5 ml of silicone casting material was injected into the joint. Injections were always made with the limb placed in the jig without loading and the hoof positioned in the neutral position. Immediately after injecting the silicone, the leg was loaded to 3000 N either in the balanced, HU, TU, or LU position (5 legs in each group). Legs were left loaded for 3 h for the silicone to cure.

Each leg was radiographed (standard lateromedial and dorsopalmar views) to see where the casting material had set (silicone is visible on radiographs). All the legs were dissected, by carefully removing the second phalanx and distal articular surface of the DIP photographed onto 35 mm film. Each DIP-joint surface and the silicone were also traced onto tracing paper. The tracing paper was transferred to graph paper and the area of the articular surface and area of silicone measured by counting squares (Brama *et al.* 2001). The surface of the DIP-joint is concave and manual quantification was therefore used instead of image analysis to obtain more accurate results. The joint was then divided sagittally through the sagittal ridge and transversely through the midpoint of the collateral ligaments, to create four quarters (dorsolateral, dorsomedial, palmarolateral and palmaromedial) and the amount of casting material in each synovial joint recess was weighed and the area measured (Fig 6). Measurements from both dorsal quarters were used to calculate silicone in the dorsal area and the same system also used to calculate palmar, lateral and medial measurements. The amount of silicone casting material in the dorsal and palmar pouches was also measured.

Statistical analysis

Comparison of means between different groups was calculated using the one-way ANOVA test.

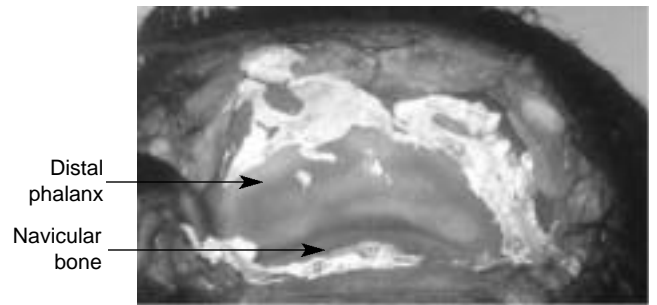


Fig 3: Silicone cast showing the contact area in toe-up orientation.

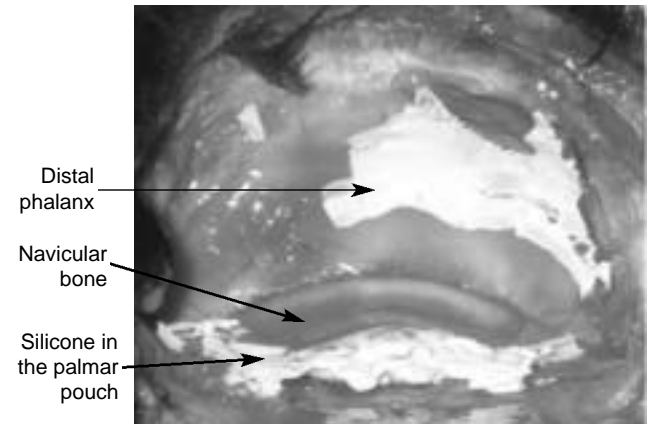


Fig 4: Silicone cast showing the contact area in lateromedial orientation.

Results

Study 1

The mean intra-articular pressures, before and after injecting 5 ml of contrast material, are presented in Table 1. When pressure was measured from 4 different sites of the DIP joint, the intra-articular pressure was found to be similar at each arthrocentesis point indicating free communication within the DIP during loading. Mean preinjection intra-articular pressure was negative in the DIP in balanced, toe-up, lateromedial and mediolateral positions but in the heel up orientation the intra-articular pressure was positive even without injecting contrast material into the joint.

After injecting the contrast material, elevating the heel increased the intra-articular pressure in the DIP at 1000 and 2000 N limb force ($P < 0.0001$) when compared to the balanced position. Elevation of the toe after injection reduced the intra-articular pressure ($P < 0.01$ at 1000 N load and $P < 0.05$ at 2000 N load). MU imbalance caused an increase in the intra-articular pressure at 1000 N ($P < 0.05$) but had no effect on the pressure at 2000 N. LU imbalance did not cause any significant alterations to the intra-articular pressure in the DIP.

Study 2

When 15 ml of silicone was used, rupture of the tendon sheath occurred in 6/8 of the limbs. Hence, in the later study 5 ml silicone was used. Radiographs revealed that most of the silicone was displaced into the dorsal and palmar pouch of the DIP, in all orientations. Dissection showed that on balanced loading, minimal silicone was seen on the joint surface (Fig 1). With the heel-up orientation, more silicone was located on the palmar aspects of the

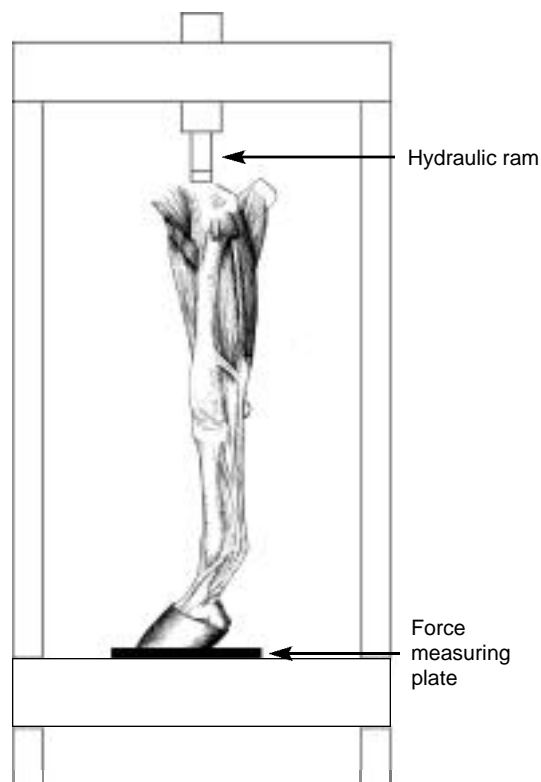


Fig 5. Diagram of the jig.

joint (Fig 2). The difference was significant for both the area and the weight of silicone ($P < 0.05$). The toe-up position caused more silicone to be found on the dorsal parts of the DIP ($P < 0.05$ for both the area and the weights) (Fig 3). With lateromedial loading, silicone was displaced ($P < 0.05$) to the nonloaded side (Fig 4). This distribution was also apparent on the radiographs. The results of the contact area of the silicone casting are presented in Table 2 and weight distribution in Table 3.

Discussion

In a preliminary study, in 5 limbs, the articular pressure was measured with a needle inserted through the dorsal pouch, via a palmar approach through the navicular bursa, through a medial approach and through a lateral approach to the DIP-joint. Pressure measurements were made with the limb in all orientations. The intra-articular pressure was found to be similar at each arthrocentesis point indicating free communication within the DIP during loading; therefore, in the main study, only the dorsal approach was used and pressure measurements were considered to apply to the whole of the joint cavity. However, joint compartmentalisation is a common feature in joints (Strand *et al.* 1995) and it is possible that in the moving horse the different parts of the joint do not communicate throughout the stride.

In healthy joints, the synovial pressure is usually subatmospheric (Levick 1983). In our study, cadaver legs, without joint distention with the contrast material, had negative pressure in normal, toe-up, lateromedial and mediolateral orientations, even under load. Raising the heels led to increased intra-articular pressure above 0 kPa in 4 out of 5 horses, even without any artificial fluid distention of the joint. In a previous study, it was found that only horses with no distention of the

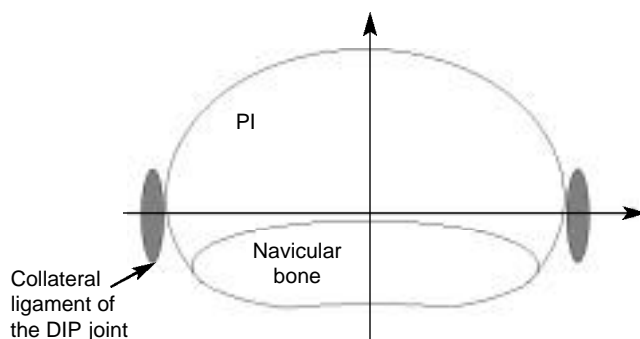


Fig 6: Diagram showing how the DIP-joint was divided.

metacarpophalangeal joint (MCP) had subatmospheric pressures (Strand *et al.* 1995). Factors such as elastance of the joint capsule are known to be involved in determining the intra-articular pressure of a joint (Geborek *et al.* 1989). If joint pressure is initially greater than normal, as occurs in diseased equine MTP joints, joint motion further increases joint capsule relaxation (compliance) and, therefore, reduces intra-articular pressure (da Gracca Macoris and Bertone 2001). Our measurements were made with the leg in a simulated standing position; joint movement, in an exercising horse, may have an effect on intra-articular pressure but was not evaluated here.

Joint distention is positively correlated with intra-articular pressure (Strand *et al.* 1995). When 15 ml of silicone casting material was injected into the DIP, it was noted that, in 6/8 of the legs, rupture of the tendon sheath occurred regardless of the orientation. Therefore, in the later study and for the measurements reported here, 5 ml silicone casting material was used. It was interesting that rupture always occurred into the tendon sheath; no leaking to the navicular bursa was noted in any legs. The DIP and the navicular bursa do not communicate (Bowker *et al.* 1993), but local anaesthetic injected into the DIP results in effective tissue concentrations of local anaesthetic agent in the synovial tissues of the navicular bursa (Keegan *et al.* 1996). Pressure in the navicular bursa may, however, rise along with DIP pressure.

Elevating the heel led to a huge increase in the DIP pressure. The increased intra-articular pressure in the joint may directly cause pain. Increase in intra-articular pressure can also decrease blood flow to the synovium and intra-articular ligaments (Hardy *et al.* 1996) which may lead to hypoxia, acidosis and decreased glucose concentration within the synovial fluid of human patients with inflammatory joint disease (James *et al.* 1990). This contributes to destructive processes within a joint. Abnormally high intra-articular pressure also causes joint instability by disrupting the close relation of the opposing articular surfaces, through the increase in intra-articular volume (Lust *et al.* 1980). Some of the possible disease-aggravating effects of this unphysiological environment also include release of lysosomal enzymes, with acceleration of the inflammatory reaction (Levick 1990).

Raising the toe decreased the intra-articular pressure in the DIP. Low heel conformation is commonly associated with distal limb problems and is thought to be a predisposing factor to navicular disease (Wright 1993). Broken back hoof/pastern axis results in extension of the DIP and causes an increase in the forces acting on the palmar soft tissues of the foot, including an increase in strain in the deep digital flexor tendon (DDFT) and, possibly,

increased concussion on the palmar structures at impact. It is topical and beneficial, to raise the heels in cases of palmar foot pain and navicular disease to reduce the forces on the palmar aspect of the foot. The results of this study indicate that even a 5° wedge increases DIP pressure and may be detrimental to joint function. The results support the view that the 'balanced' foot is the ideal.

Inappropriate mediolateral balance has been associated with various forms of lameness including sheared heels, chronic heel soreness, quarter and heel cracks, side-bones and chronic metacarpophalangeal synovitis (Balch *et al.* 1995). On the other hand, bone-strain studies (Firth *et al.* 1988) and instrumented force-shoe trials (Barrey 1990), provide evidence that unequal weight bearing is a normal aspect of the gait of sound horses. Mediolateral imbalance did not seem to have an effect on the intra-articular pressure of the DIP. Differences noted with 1000 N loading, might be due to the fact that positioning the plastic wedge, on the medial side under the hoof, led to a slight raising of one heel at the same time.

With the normal 'balanced' foot orientation, there was good contact between the joint surfaces and most of the silicone was squeezed away from the entire articular surface during loading. This would indicate that, in this position, there was the largest and most even contact area between the proximal and distal joint surfaces of the DIP and, therefore, the least pressure per unit area. Wedging and any alterations of the foot orientation resulted in silicone remaining on the articular surface on the wedged side. This indicates uneven load distribution across a joint and localised higher pressures on the contact cartilage surfaces, with any deviation from the 'balanced' foot position. *In vivo*, this would lead to greater localised 'wear and tear' on the joint surface and possibly a greater tendency to degenerative joint disease.

Corrective farriery aims to restore foot balance. It is directed at relieving force concentrations in specific areas and distributing the forces associated with weightbearing evenly across the foot. Different, often contradictory, practices are frequently used for the same problem. In laminitic horses, some farriers prefer elevating the heels while others lower the heels. Elevating the heel is thought to relieve the pressures on the foot in the navicular region and is a common practice in navicular disease and bone spavin. Heel wedges raise the heels, reduce the extension of the DIP and decrease the strain in the deep digital flexor tendon and navicular region (Willemsen *et al.* 1999). However, heel wedges can increase the forces acting on the heel region and may lead to further heel collapse (Ostblom *et al.* 1982). Raising the heel may also lead to a higher risk of superficial deep flexor tendon damage (Riemersma *et al.* 1996). The increasing range of horseshoes and hoofpads commercially available makes it important to be able to evaluate their influence on performance and stress on the locomotor apparatus.

This *in vitro* study has shown that changes in hoof-angle resulted in a redistribution of load over the DIP and alterations in the intra-articular pressure within the joint. Clearly, to evaluate the overall effects of foot balance on the anatomical structures of the foot, it will be necessary to combine DIP data with information on pressures in the navicular bursa, studies on strains in the deep digital flexor tendon and calculation of shear forces in the pedal laminae. Therefore, it is important that further studies are conducted into the changes in the foot when the hoof angle is altered, including ultimately the measurements of these effects *in vivo*.

Acknowledgements

This research was kindly sponsored by Finnish Veterinary Foundation, Orion-Pharmos and The Home for Rest for Horses.

Manufacturers' addresses

¹Kistler Instrumente AG Winterthur, Switzerland.

²National Instruments, Newbury, Berkshire, UK.

³RS Components Ltd, Corby, Northamptonshire, UK.

⁴Schering Health Care Limited, Burgess Hill, West Sussex, UK.

References

- Arnoldi, C., Reimann, I., Mortensen, S., Christensen, S., Kristoffersen, J., Sonnichsen, H. and Smith, M. (1980) The effect of joint position on juxta-articular bone marrow pressure. Relation to intra-articular pressure and joint effusion - an experimental study on horses. *Acta Orthop. Scand.* **51**, 893-897.
- Balch, O., White, K., Butler, D. and Metcalf, S. (1995) Hoof balance and lameness: improper toe length, hoof angle and mediolateral balance. *Comp. cont. Educ. pract. Vet.* **17**, 1275-1283.
- Barrey, E. (1990) Investigation of the vertical hoof force distribution in the equine forelimb with an instrumented horse boot. *Equine vet. J., Suppl.* **9**, 35-38.
- Bowker, R., Rockershouser, S., Vex, K., Sonea, I., Caron, J. and Kotyk, R. (1993) Immunocytochemical and dye distribution studies of nerves potentially desensitised by injections into the distal interphalangeal joint or the navicular bursa of horses. *J. Am. vet. med. Ass.* **203**, 1708-1714.
- Brama, J., Karsenberg, A., Barneveld, A. and van Weeren, P. (2001) Contact areas and pressure distribution on the proximal articular surface on the proximal phalanx under sagittal plane loading. *Equine vet. J.* **33**, 26-32.
- Curtis, S., Ferguson, D., Luikart, R. and Ovnicek, G. (1999) Trimming and shoeing the chronically affected horse. *Vet. Clin. N. Am.: Equine Pract.* **15**, 463-480.
- Da Graça Macoris, D. and Bertone, A. (2001) Intra-articular pressure profiles of the cadaveric fetlock joint in motion. *Equine vet. J.* **33**, 184-190.
- Degueurce, C., Chateau, H., Pasqui-Boutard, V., Pourcelot, P., Audigie, F., Crevier-Denoix, N., Jerbi, H., Geiger, D. and Denoix, J.M. (2000) Concrete use of the joint coordinate system for the quantification of articular rotations in the digital joints of the horse. *Vet. Res.* **1**, 297-311.
- Firth, E.C., Schamhardt, H.C. and Hartman, W. (1988) Measurements of bone strains in foals with altered foot balance. *Am. J. vet. Res.* **49**, 261-265.
- Geborek, P., Moritz, U. and Wollheim, F. (1989) Joint capsule stiffness in knee arthritis. Relationship to intra-articular volume, hydrostatic pressures and extensor muscle function. *J. Rheumatol.* **16**, 1351-1358.
- Goddard, N. and Gosling, P. (1988) Intra-articular fluid pressure and pain in osteoarthritis of the hip. *J. Bone Surg.* **70**, 52-55.
- Hardy, J., Bertone, A. and Muir, W. (1996) Joint pressure influences synovial tissue blood flow as determined by colored microspheres. *J. appl. Physiol.* **80**, 1225-1232.
- Hood, D. (1999) Laminitis as a systemic disease. *Vet. Clin. N. Am.: Equine Pract.* **15**, 481-494.
- James, M., Cleland, L., Rofe, A. and Leslie, A. (1990) Intraarticular pressure and the relationship between synovial perfusion and metabolic demand. *J. Rheumatol.* **17**, 521-527.
- Jawed, S., Gaffney, K. and Blake, D. (1997) Intra-articular pressure profile of the knee joint in a spectrum of inflammatory arthropathies. *Ann. Rheum. Dis.* **56**, 686-689.
- Keegan, K., Wilson, A., Kreeger, J., Ellersieck, M., Kuo, M. and Zhaolin, L. (1996) Local distribution of mepivacaine after distal interphalangeal joint injection in horses. *Am. J. vet. Res.* **57**, 422-426.
- Kramer, J., Yelin, E. and Epstein, W. (1983) Social and economic impacts of four musculoskeletal conditions. *Arthritis Rheum.* **26**, 901-907.
- Levick, J. (1983) Joint pressure and volume studies, Their importance, design and interpretation. *J. Rheumatol.* **10**, 353-357.
- Levick, J. (1990) Hypoxia and acidosis in chronic inflammatory arthritis; relation to vascular supply and dynamic effusion pressure. *J. Rheumatol.* **17**, 579-582.
- Lohmander, S. (1994) Biomechanical changes in cartilage in osteoarthritis. In: *Structure and Function of Articular Cartilage*, Eds: V. C. Mow and T. Ratcliffe, CRC Press, Boca Raton, USA.
- Lust, G., Beilman, W., Dueland, D. and Farrell, P. (1980) Intra-articular volume and hip joint instability in dogs with hip dysplasia. *J. Bone Jt. Surg. Am.* **62**, 576-582.

- Merkens, H., Schamhardt, H., van Osch, G. and Van der Bogert, A. (1993) Ground reaction force patterns of Dutch Warmblood horses at normal trot. *Equine vet. J.* **25**, 134-137.
- Ostblom, L., Lund, C. and Melsen, F. (1982) Histological study of navicular bone disease. *Equine vet. J.* **14**, 199-202.
- Riemersma, D., van den Bogert, A., Jansen, M. and Schamhardt, H. (1996) Influence of shoeing on ground reaction forces and tendon strains in the forelimbs of ponies. *Equine vet. J.* **28**, 126-132.
- Rossdale, P., Hopes, R., Digby, N. and Offord, K. (1985) Epidemiological study of wastage among racehorses 1982, 1983. *Vet. Rec.* **19**, 116, 66-69.
- Strand, E., Martin, G., Crawford, M., Kamerling, S. and Burba, D. (1998) Intra-articular pressure, elastance and range of motion in healthy and injured racehorse metacarpophalangeal joints. *Equine vet. J.* **30**, 520-527.
- Strand, E., Martin, G., Crawford, M., Kamerling, S., Burba, D. and Kearney, M. (1995) Intra-articular pressure, elastance and range of motion in flexion of the equine metacarpophalangeal joint. *Am. J. vet. Res.* **56**, 1362-1371.
- Willemsen, M., Savelberg, H. and Barneveld, A. (1999) The effect of orthopaedic shoeing on the force exerted by the deep digital flexor tendon on the navicular bone in horses. *Equine vet. J.* **31**, 25-30.
- Wilson, A., Seelig, T., Shield, R. and Silverman, B. (1998) The effect of foot imbalance on point of force application in the horse. *Equine vet. J.* **30**, 540-545
- Wilson, A., McGuigan, P., Su, A. and van den Bogert, A. (2001) Horses damp the spring in their step. *Nature* **414**, 895-899.
- Wright, I. (1993) A study of 118 cases of navicular disease, clinical features. *Equine vet. J.* **25**, 488-492
- Vegter, J. (1987) The influence of joint posture on intra-articular pressure. A study of transient synovitis and Perthes' disease. *J. Bone Jt. Surg.* **69**, 71-74.
- Wood, L., Ferrell, W. and Baxendale, R. (1988) Pressure in normal and acutely distended human knee joints and effects on quadriceps maximal voluntary contractions. *Q.J. expt. Physiol.* **73**, 305-314.
- Wyn-Jones, G. (1988) The distal interphalangeal joint. In: *Equine Lameness*, Blackwell Scientific Publications, UK. p 64.

Received for publication: 25.6.01

Accepted: 23.5.02